



**A Khalil**

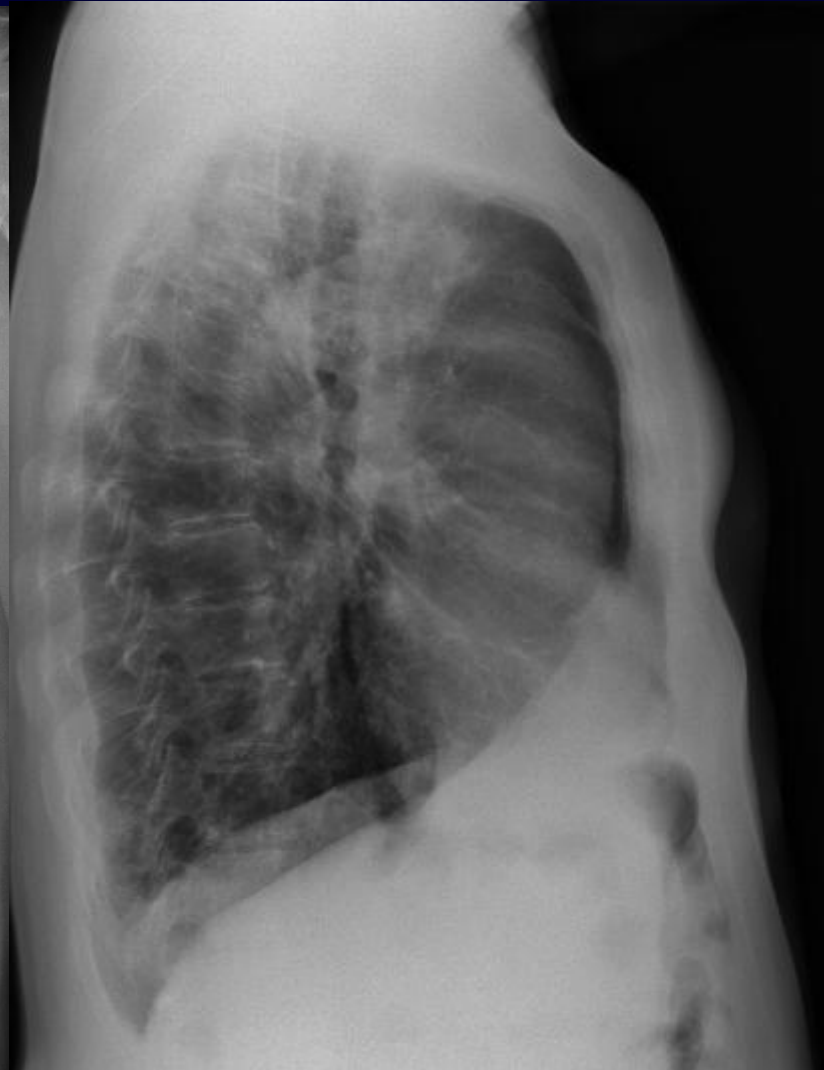
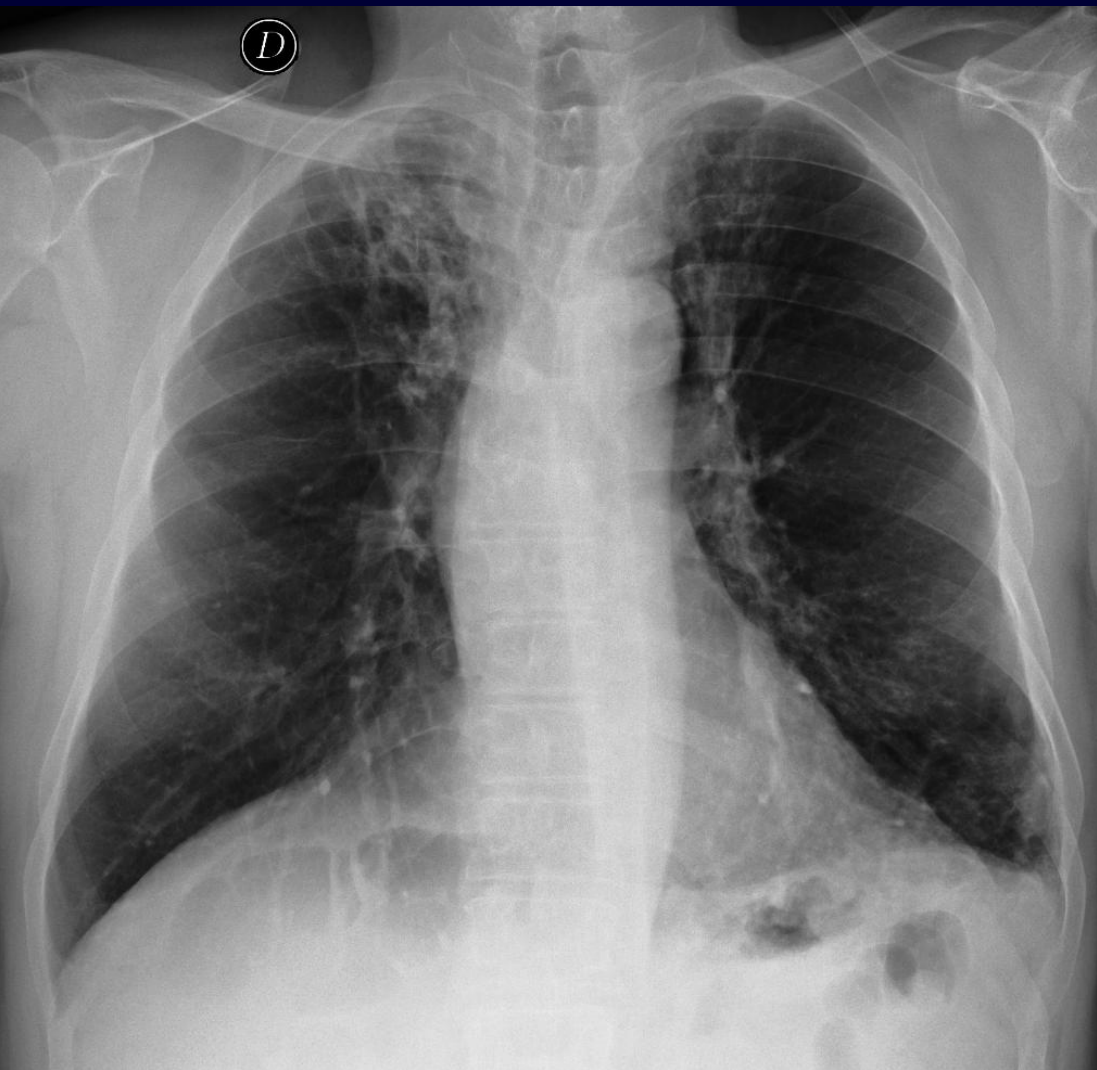
**MF Carette**

Homme de 68 ans

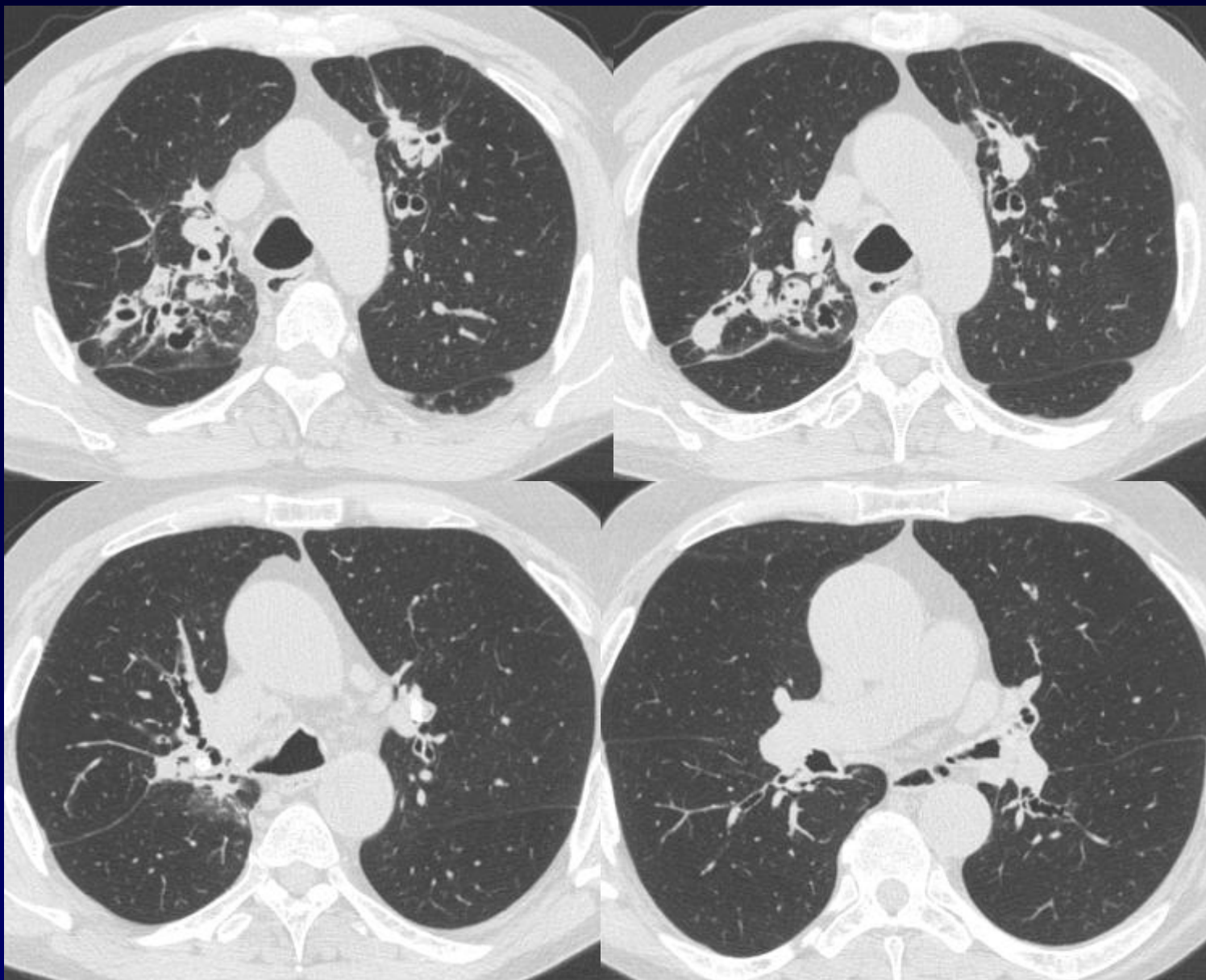
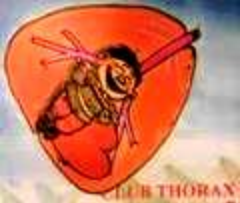1988: Invalidité pour insuffisance respiratoire

Tabac: 30 paquets-année

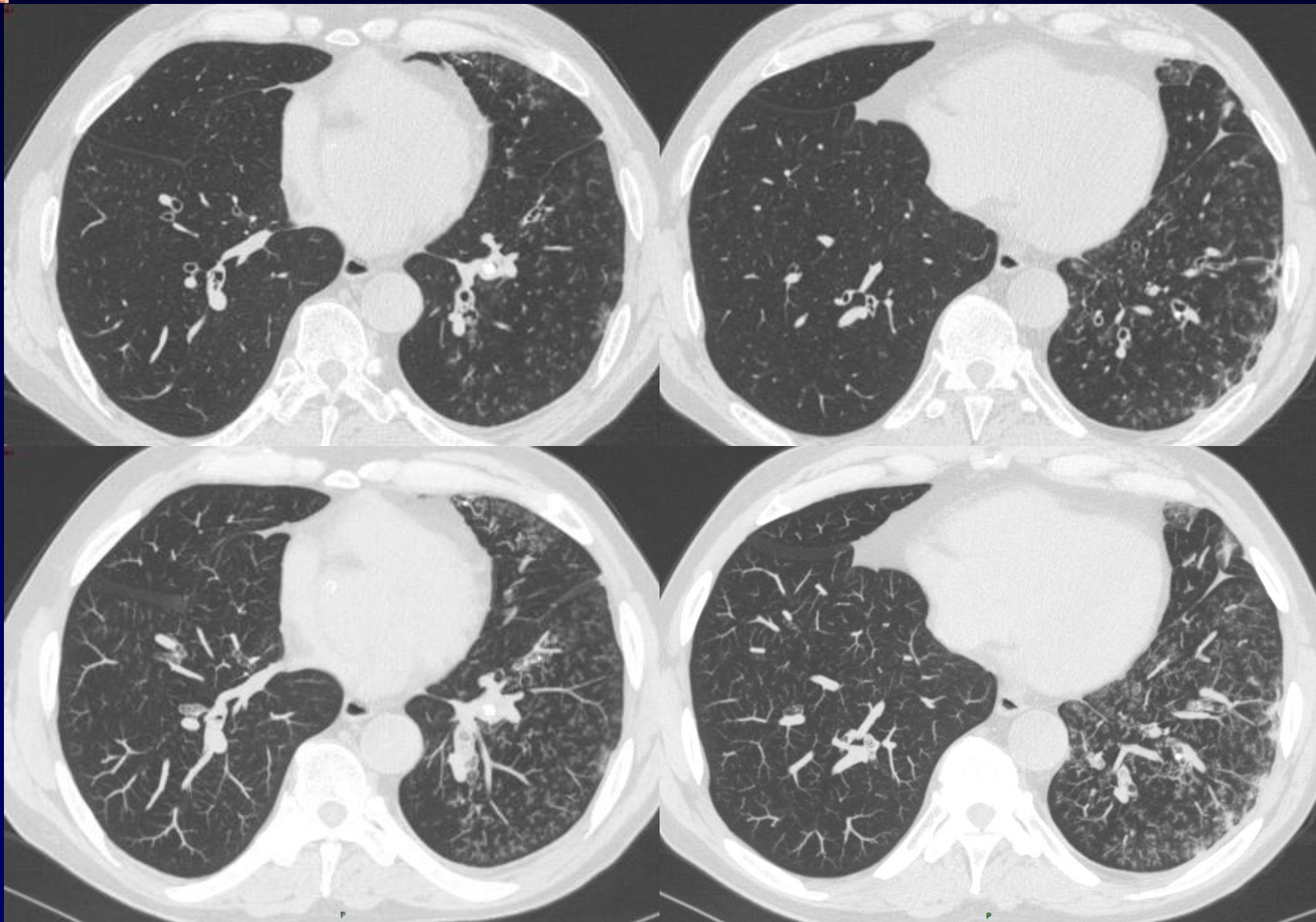
2009: Anomalies du lobe supérieur droit



01 / 2009

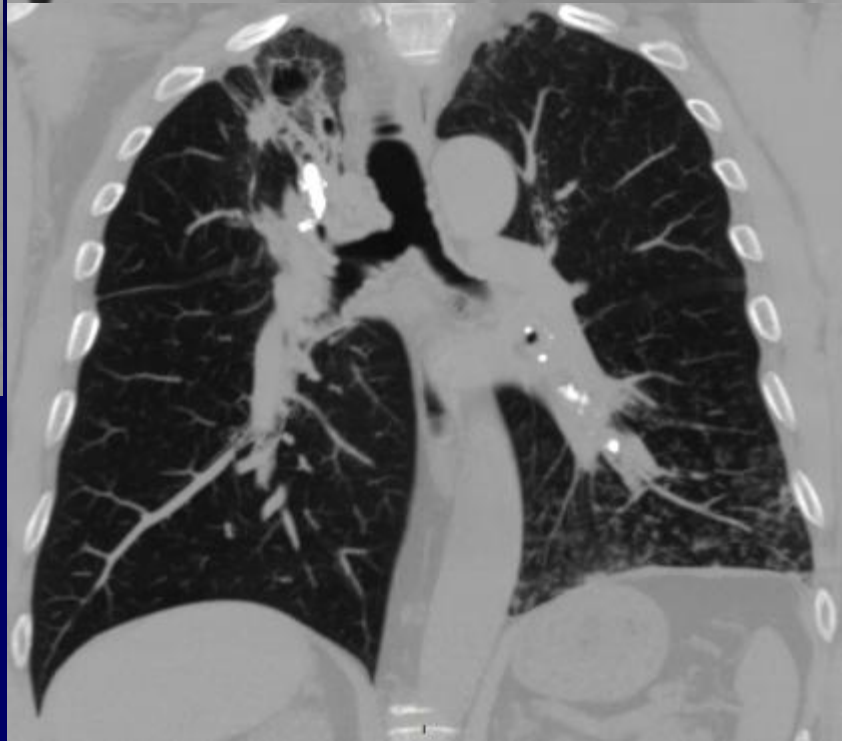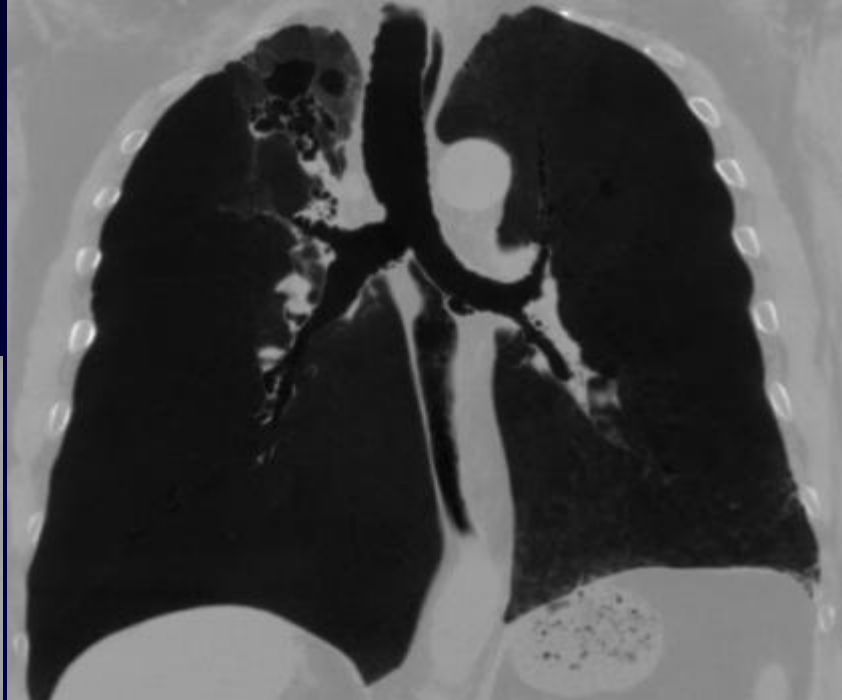

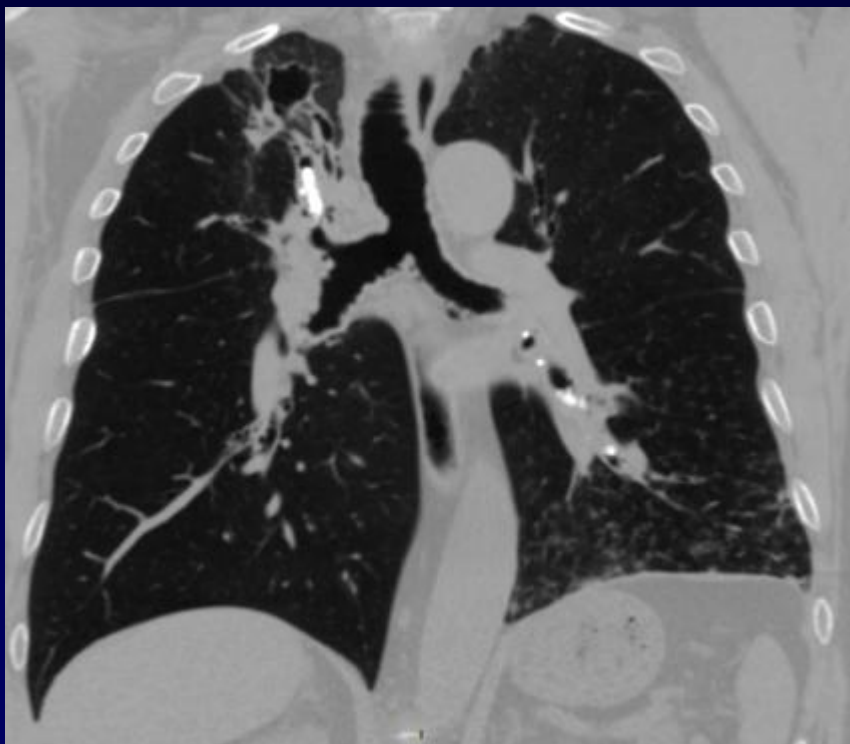
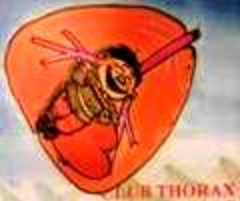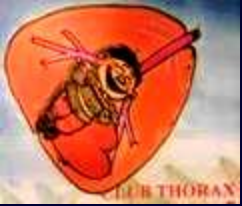01 / 2009



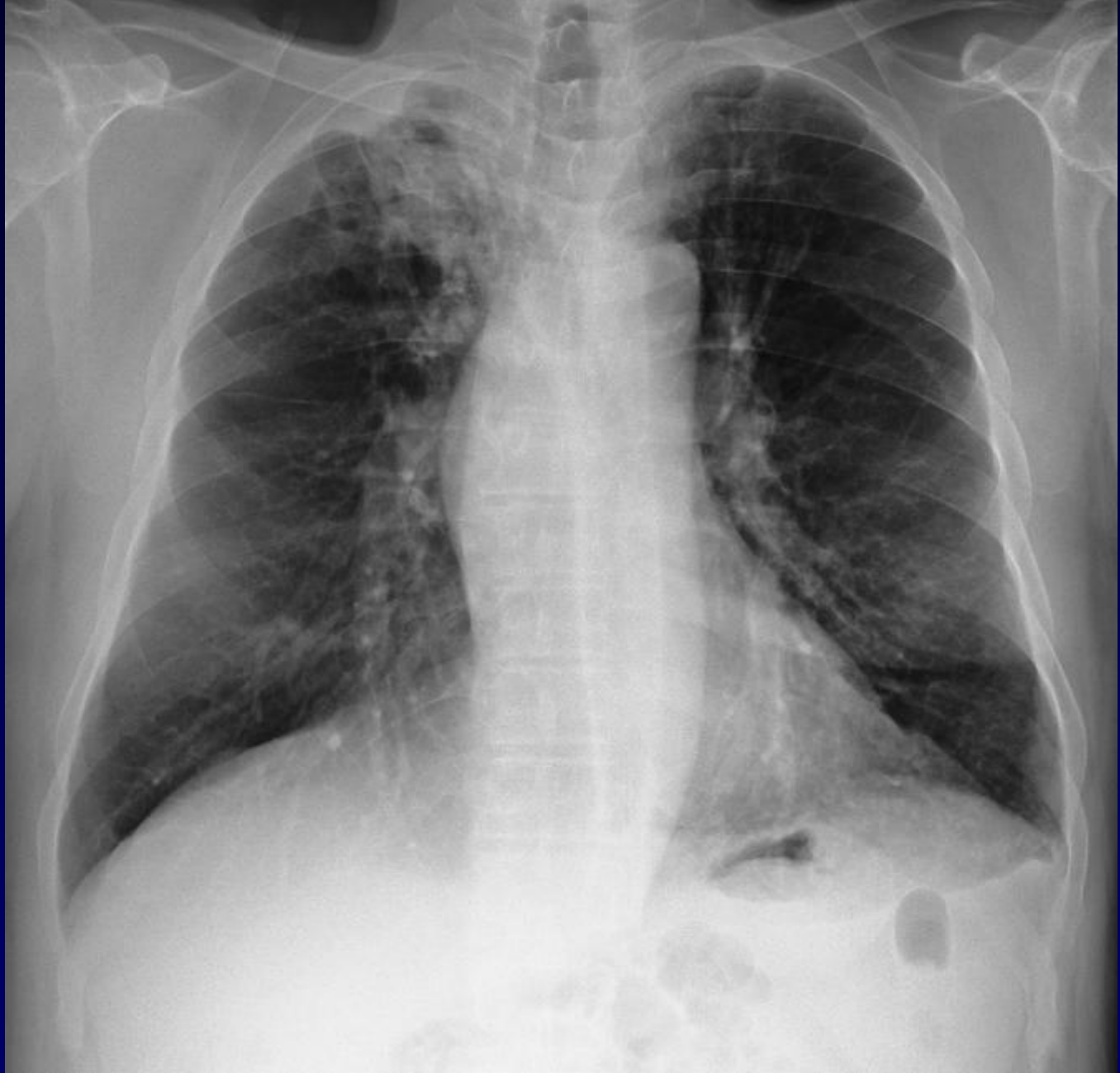
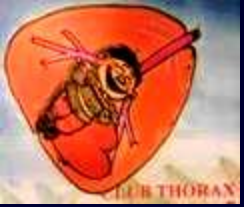
**Diagnostic ?**

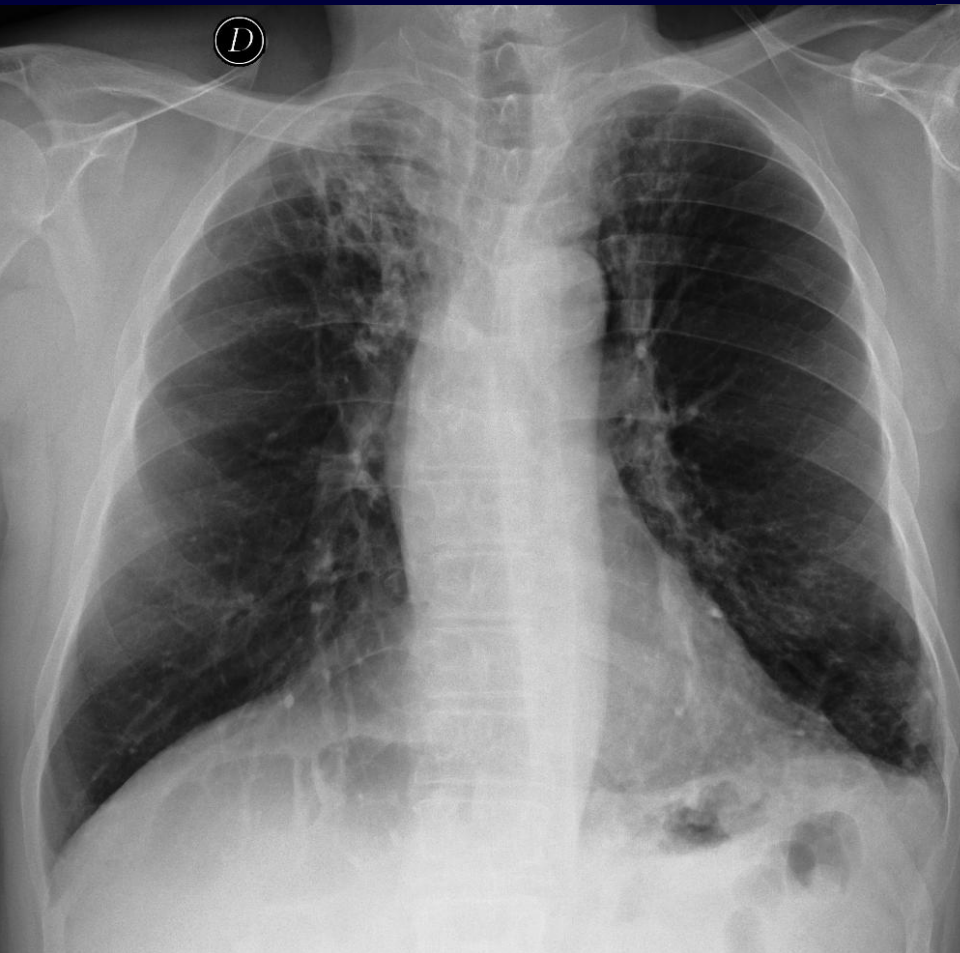




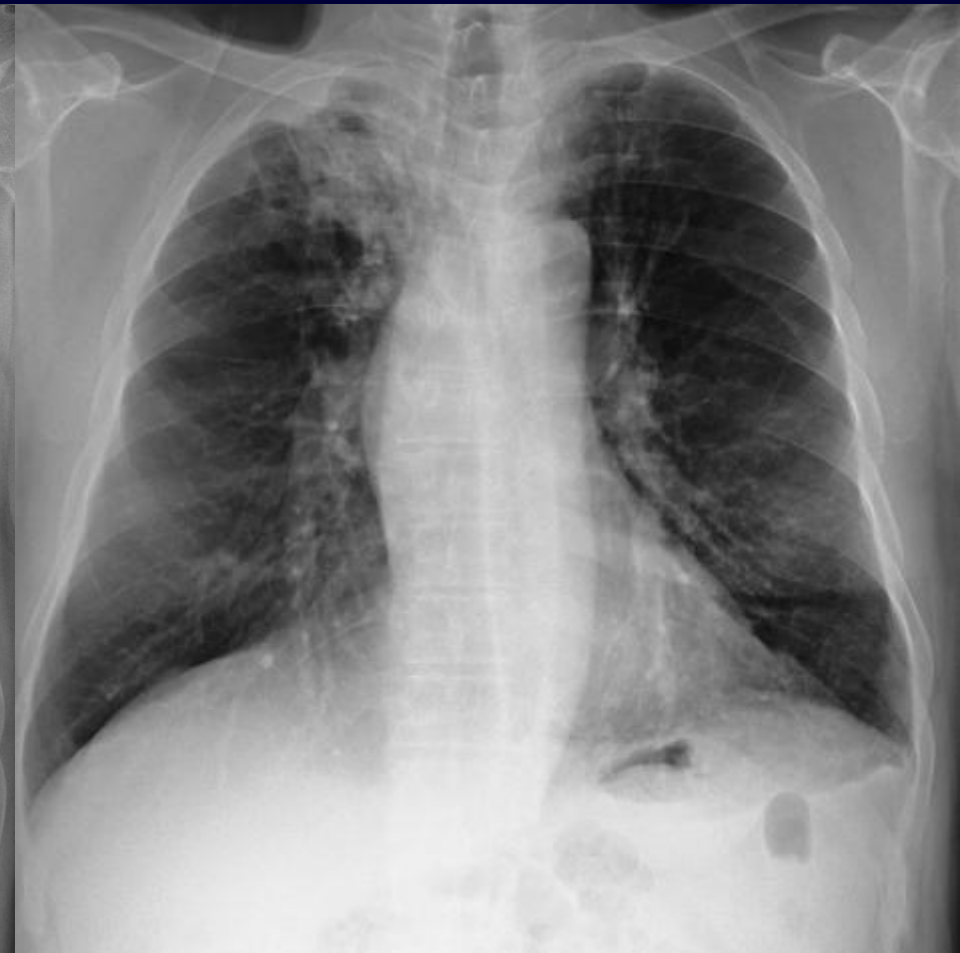- 11/2010: Aggravation des signes respiratoires
- Quelques crachats hémoptoïques
- Présence de filaments aspergillaires
- Bilan radiologique



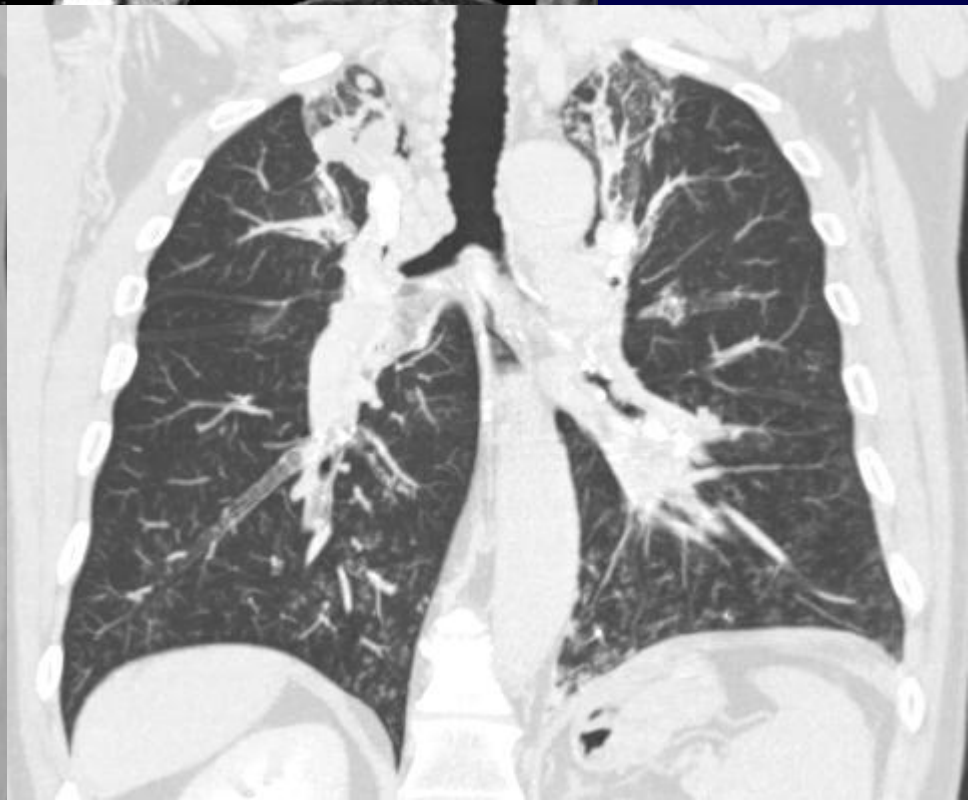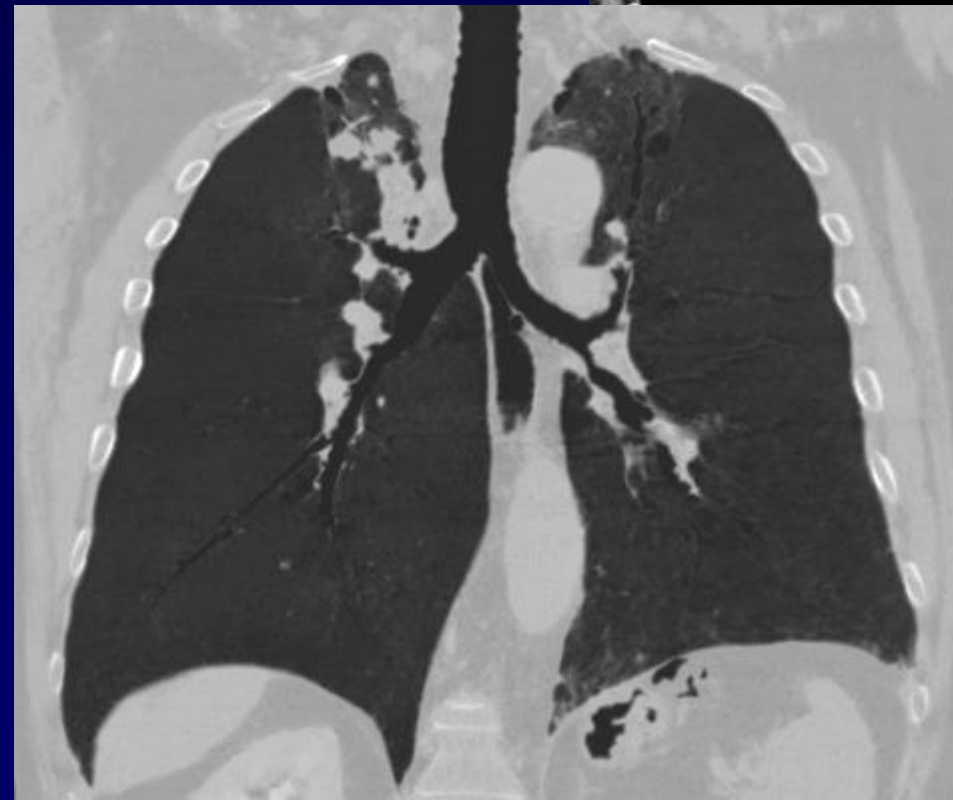
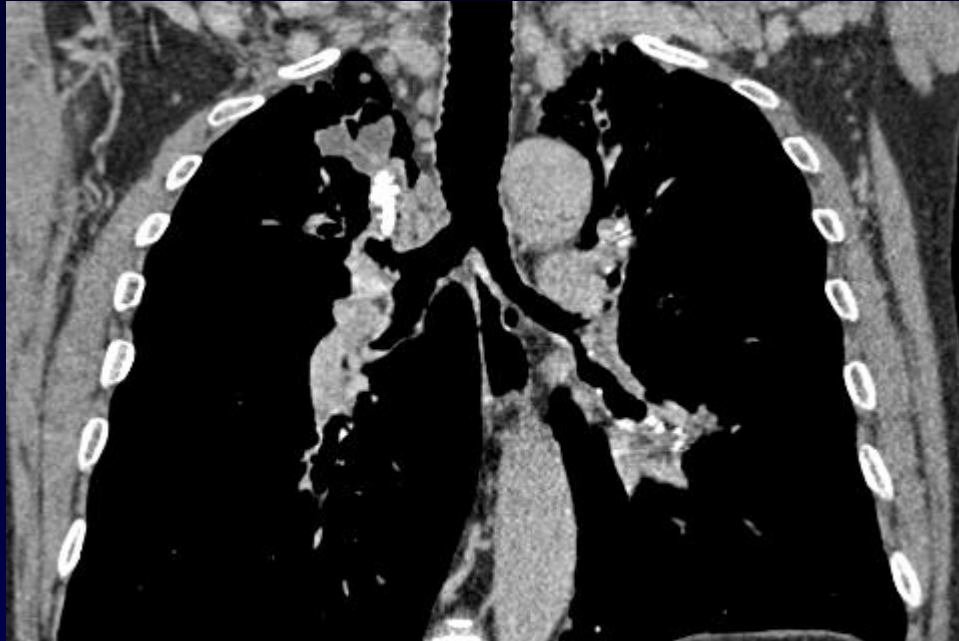
**11 / 2010**

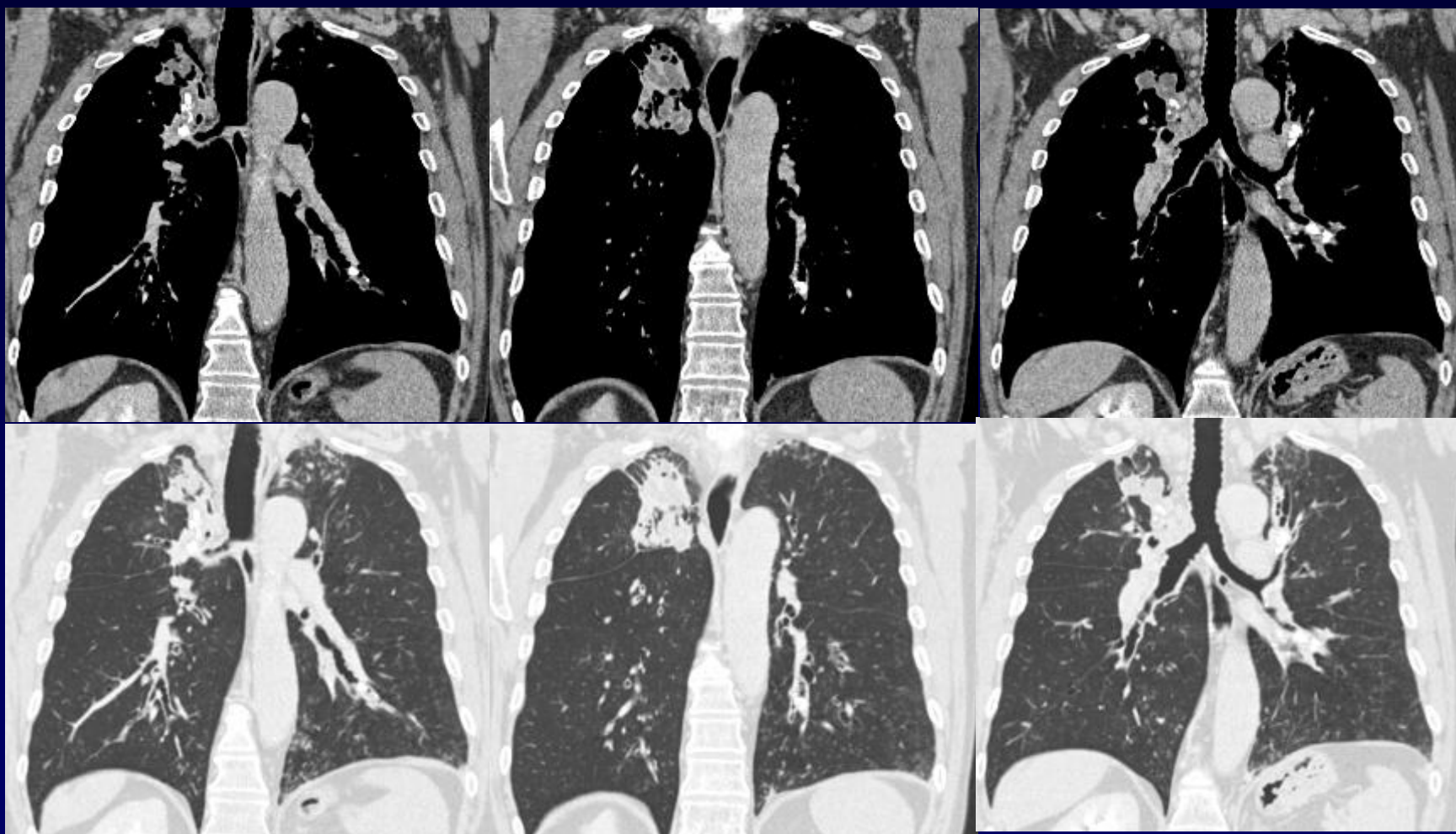


**1 / 2009**



**11 / 2010**







## Diagnostic

Broncholithiases multiples avec dilatation des bronches sur séquelles de tuberculose avec colonisation aspergillaire